



Guidelines for the Management of Hiatal Hernia

Geoffrey P Kohn MBBS(Hons) MSurg FRACS, Raymond R Price MD FACS, Steven R Demeester MD FACS, Joerg Zehetner MD, Oliver J Muensterer MD, Ziad T Awad MD FACS, Sumeet K Mittal MD FACS, William S Richardson MD FACS, Dimitrios Stefanidis MD PhD FACS, Robert D Fanelli MD FACS and the SAGES Guidelines Committee

Preamble

The guidelines for the management of hiatal hernia are a series of systematically developed statements to assist physicians' and patients' decisions about the appropriate use of laparoscopic surgery for hiatal hernia. The statements included in this guideline are the product of a systematic review of published literature on the topic, and the recommendations are explicitly linked to the supporting evidence. The strengths and weaknesses of the available evidence are highlighted and expert opinion sought where the evidence is lacking.

Disclaimer

Guidelines for clinical practice are intended to indicate preferable approaches to medical problems as established by experts in the field. These recommendations will be based on existing data or a consensus of expert opinion when little or no data are available. Guidelines are applicable to all physicians who address the clinical problem(s) without regard to specialty training or interests, and are intended to indicate the preferable, but not necessarily the only acceptable approaches due to the complexity of the healthcare environment. Guidelines are intended to be flexible. Given the wide range of specifics in any health care problem, the surgeon must always choose the course best suited to the individual patient and the variables in existence at the moment of decision. Guidelines are developed under the auspices of the Society of American Gastrointestinal and Endoscopic Surgeons and its various committees, and approved by the Board of Governors. Each clinical practice guideline has been systematically researched, reviewed and revised by the Guidelines Committee (Appendix 1), and reviewed by an appropriate multidisciplinary team. The recommendations are therefore considered valid at the time of its production based on the data available. Each guideline is scheduled for periodic review to allow incorporation of pertinent new developments in medical research knowledge, and practice.

Literature review methodology

A large body of literature exists on the management of hiatal hernia. A systematic literature search was performed on PubMed in February 2011. A further search directed towards the pediatric literature was performed in February 2013. The search strategies were limited to human articles and are shown in Appendix 2.

392 relevant articles in the past 5 years were identified. The pediatric-specific search yielded 52 articles. The abstracts were reviewed and divided into the following categories:



- a. Randomized studies, meta-analyses, and systematic reviews
- b. Prospective studies
- c. Retrospective studies
- d. Case reports
- e. Review articles

Randomized controlled trials, meta-analyses, and systematic reviews were selected for further review, along with prospective and retrospective studies that included at least 20 patients. Studies with smaller samples were considered when additional evidence was lacking, and if a specific point was highlighted. The most recent reviews were also included. All case reports, older reviews, and smaller studies were excluded. According to these exclusion criteria, 153 articles were reviewed. A further 15 references were included in the pediatric-specific search, after exclusions. Whenever the available evidence from high quality studies was considered to be adequate, lower evidence level studies were not considered. Duplicate publications were considered only once.

The reviewers graded the level of evidence and manually searched the bibliography of each article for additional articles that may have been missed during the original search. This stage of the search continued to November 2011. The additional relevant articles (n = 96) found were also included in the review. A total of 248 graded articles relevant to this guideline were reviewed. To facilitate review by multiple reviewers, these articles were divided into the following topics:

- a. Definitions, classification and pathophysiology
- b. Diagnosis
- c. Natural history and indications for surgery
- d. Preoperative assessment
- e. Technical considerations
 - i. Transthoracic vs. transabdominal
 - ii. Hernia sac excision vs. simple reduction
 - iii. Laparoscopic vs. open
 - iv. Mesh cruroplasty vs. no reinforcement
 - v. Fundoplication vs. no antireflux procedure
 - vi. Gastropexy vs. no gastric fixation
- f. Outcome
- g. Predictors of success
- h. Revisional surgery
- i. Pediatric considerations

Both the quality of the evidence and the strength of the recommendation for each of the below guidelines was assessed according to the GRADE system described in Table 1. There is a 4-tiered system for quality of evidence (very low (+), low (++) , moderate (+++), or high (++++)) and a 2-tiered system for strength of recommendation (**weak** or **strong**). Further definitions are provided by SAGES in "[The Definitions Document: A Reference for Use of SAGES Guidelines](#)". Where current literature does not support a conclusion, the opinion of experts in the field is offered in order that the reader may make informed management decisions.



Limitations of the available literature

Despite the availability of several randomized controlled trials and meta-analyses, most available studies are either prospective or retrospective reports. Several limitations exist in the examined literature. First, the general methodological quality of the available trials is low due to small patient numbers, inadequate trial design or methodology, lack of standardization, and lack of objective outcome assessment¹. Only a few studies report a power analysis and define a main outcome variable. Thus, the validity of several of the pooled analyses of the available meta-analyses is hampered by statistically significant heterogeneity related to small sample size. In addition, the reporting of outcomes varies significantly, as does the follow-up period, making it difficult to combine and compare such data. Furthermore, there are several differences in the surgical technique used that may directly impact the outcomes of interest and introduce bias into the reported outcomes. Much of the literature regarding the management of hiatal hernias refers only to certain subtypes; other subtypes, particularly large symptomatic sliding Type I hernias are often overlooked, yet require coverage by these guidelines. Finally, the majority of the studies do not report details on the expertise of their surgeons, and most have been conducted in single institutions, making generalization of their findings difficult.

Introduction

Hiatal hernia is a common disorder^{3, 4}. It is characterized by a protrusion of any abdominal structure other than the esophagus into the thoracic cavity through a widening of the hiatus of the diaphragm.

Definitions and etiology

Attempts began early in the last century to classify hiatal hernia into subtypes⁵. The current anatomic classification has evolved to include a categorization of hiatal hernias into Types I – IV.

1. **Type I** hernias are sliding hiatal hernias, where the gastroesophageal junction migrates above the diaphragm⁶. The stomach remains in its usual longitudinal alignment⁷ and the fundus remains below the gastroesophageal junction.
2. **Type II** hernias are pure paraesophageal hernias (PEH); the gastroesophageal junction remains in its normal anatomic position but a portion of the fundus herniates through the diaphragmatic hiatus adjacent to the esophagus.
3. **Type III** hernias are a combination of Types I and II, with both the gastroesophageal junction and the fundus herniating through the hiatus. The fundus lies above the gastroesophageal junction.
4. **Type IV** hiatal hernias are characterized by the presence of a structure other than stomach, such as the omentum, colon or small bowel within the hernia sac.

Greater than 95% of hiatal hernias are Type I. Types II – IV hernias as a group are referred to as paraesophageal hernias (PEH), and are differentiated from Type I hernias by relative preservation of posterolateral phrenoesophageal attachments around the gastroesophageal



junction⁸. Of the paraesophageal hernias, more than 90% are Type III, and the least common is Type II⁷. The term “giant” paraesophageal hernia appears frequently in the literature, though its definition is inconsistent. Various authors have suggested giant paraesophageal hernias be defined as all type III and IV hernias, but most limit this term to those paraesophageal hernias having greater than 1/2 of the stomach in the chest^{10, 11, 12}.

These guidelines are specific for each type of hiatal hernia since the implications of a hiatal hernia and the indications for repair differ between the sliding (Type I) hernias and for the paraesophageal hernias (Type II, III and IV).

Cephalad migration of the gastroesophageal junction may result from weakening of the phrenoesophageal ligament. Depletion of elastin fibers leads to stretching of the ligament and proximal displacement of the gastroesophageal junction¹³. Most cases of hiatal hernia are acquired rather than congenital, though familial clustering has been reported and in a very small number of cases, multifactorial inheritance may play a part¹⁴.

Other diaphragmatic hernias exist but are not included in this review. These include acquired hernias such as traumatic diaphragmatic hernias; the rare parahiatal hernias in which the hernia defect arises lateral to the crural musculature and not through the esophageal hiatus itself; iatrogenic diaphragmatic hernias such as those that misguides chest tubes or after thoracoabdominal incisions in which the diaphragm is taken down⁷; and congenital diaphragmatic defects such as posterolateral Bochdalek hernias and retrosternal Morgagni hernias.

Recurrent hiatal hernias are included in this review. Some authors advocate that any hernia seen on postoperative radiological contrast imaging or on gastroscopy is classified as a recurrence^{15,16}. Other authors limit the definition of recurrence to those greater than 2cm in length¹⁷. Importantly, most reports indicate that small recurrences are seldom clinically significant¹⁸.

Gastric volvulus is a rare condition characterized by pathological rotation of the stomach, most commonly associated with paraesophageal hiatal hernias. Gastric volvulus can occur in the abdomen or in the chest, and can be classified according to the axis of rotation; organoaxial and mesenteroaxial. Organoaxial is the most common type, with rotation occurring about the long axis of the stomach connecting the gastroesophageal junction to the pylorus. Mesenteroaxial with rotation about the short axis of the stomach, bisecting the lesser and greater curvature, is less common. A combination of the two may exist. Primary gastric volvulus has no causative condition but the more common secondary gastric volvulus is associated with underlying conditions such as paraesophageal hernias, connective tissue disorders and anterior abdominal wall defects. Although gastric volvulus has been reported in all ages, it is more often diagnosed in elderly patients. Hiatal hernia with intrathoracic acute gastric volvulus usually presents with progressive chest pain, severe vomiting, and epigastric distention. The classical Borchardt's triad, which comprises severe epigastric pain, unproductive retching, and inability to pass a nasogastric tube, represent total gastric obstruction¹⁹.

Diagnosis

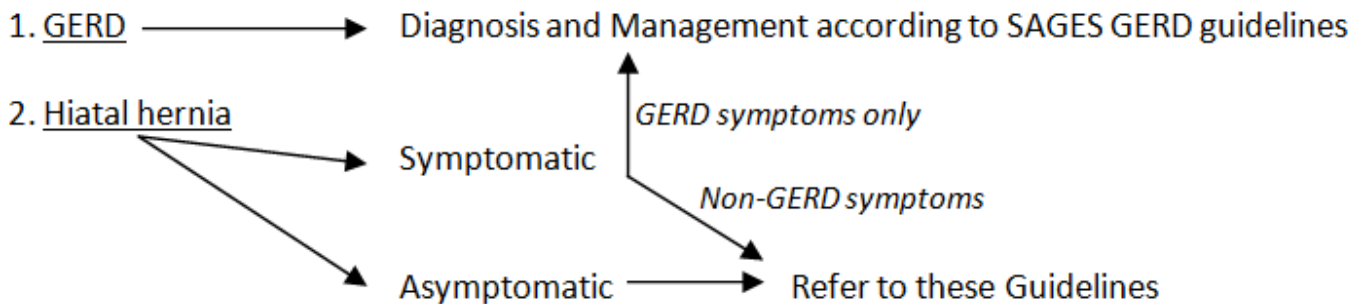


Guideline 1

- Hiatal hernia can be diagnosed by various modalities. Only investigations which will alter the clinical management of the patient should be performed (**+++**, **strong**)

The diagnostic pathway for sliding hiatal hernias overlaps with that of gastroesophageal reflux disease (GERD) [Figure 1]. Diagnosis of hiatal hernias is described in this document. Diagnosis of GERD has been described in a [previous SAGES publication](#)²⁰.

Figure 1: Diagnostic pathway for GERD and for hiatal hernia



Plain chest radiographs may identify soft tissue opacity with or without an air fluid level within the chest. A retrocardiac air-fluid level on chest x-ray is pathognomonic for a paraesophageal hiatal hernia. Visceral gas may be seen in cases of intestinal herniation. Also, loops of bowel may be visualized running in an unusual vertical pattern towards the sac, and a characteristic displacement or upward deformity of the transverse colon may be seen in cases of colon herniation²¹.

Contrast studies are helpful to gauge the size and reducibility of the hiatal hernia and to localize precisely the gastroesophageal junction in relation to the esophageal hiatus. Contrast findings may add to suspicion of existing short esophagus²². This may allow for the surgeon to be prepared to address a short esophagus with a lengthening procedure if needed intra-operatively. Further, when performed as a video-esophagram, information on bolus transport is provided by the study. Barium is the contrast agent most frequently reported in the literature as used for this purpose. Given the increased aspiration risk of patients with paraesophageal hernias presenting with acute gastric outlet obstruction, ionic water soluble contrast should be generally avoided due to the risk of aspiration pneumonitis²³.

Computed tomography (CT) scan may be useful in an urgent situation for patients with suspected complications from a volvulized paraesophageal hernia. The hernia site and any herniated organs within the chest cavity are clearly visualized in most cases. Multi-slice CT with



sagittal, coronal, and 3D reformatted images has increased the sensitivity of CT for the detection of hiatal hernia²⁴. If intestinal obstruction and strangulation occur, dilated intestinal segments will be visualized with air-fluid levels within the chest cavity and abdomen. Cephalad migration of the gastroesophageal junction or gastric fundus through the hiatus can be clearly visualized on oral contrast-enhanced CT images.

Esophagogastroduodenoscopy (EGD) allows visual assessment of the mucosa of the esophagus, stomach and duodenum. The presence of erosive esophagitis or Barrett's esophagus can be determined. Further, the size and type of hernia can be determined. Inability or difficulty reaching the duodenum in the presence of a large hiatal hernia is diagnostic of a volvulized paraesophageal hernia. Evaluation of gastric viability is particularly important among patients undergoing emergency surgery for incarcerated hernias.

Esophageal manometry can demonstrate the level of the diaphragmatic crura, the respiratory inversion point and the location of the lower esophageal sphincter. The size of the sliding component of a hiatal hernia can then be calculated, particularly with new high resolution motility technology. In patients with a paraesophageal hiatal hernia placement of the manometry catheter across the lower esophageal sphincter and below the diaphragm can be difficult^{25, 26}. Expert opinion suggests that contrast swallow showing normal motility may replace the need for a catheter-based manometry study in patients with a paraesophageal hiatal hernia. However, an esophageal motility study is critical to enable a pH probe to be properly positioned above the lower esophageal sphincter in patients with a sliding hiatal hernia and symptoms of gastroesophageal reflux.

pH testing has limited relevance in the diagnosis of a hiatal hernia, but is critical to identify the presence of increased esophageal acid exposure in patients with sliding hiatal hernias that might benefit from antireflux surgery. Confirmation of abnormal gastroesophageal reflux either by the identification of erosive esophagitis or Barrett's esophagus on upper endoscopy, or by demonstration of increased esophageal acid exposure on pH monitoring is necessary prior to consideration of operative intervention in patients with a sliding hiatal hernia.

*Nuclear medicine studies*²⁷, *transesophageal echocardiogram*²⁸ and *endoscopic ultrasound* can also demonstrate hiatal hernias but are not routinely used for diagnosis.

The mainstays of evaluation for patients with a hiatal hernia, particularly prior to operative intervention, are upper endoscopy and barium swallow. Contrast studies are reported to be more sensitive than endoscopy in detecting sliding hiatal hernia, at least in the bariatric population²⁹. The role of the various diagnostic techniques may depend on the clinical presentation of the patient. Incidentally detected hiatal hernias, or those hernias which are minimally symptomatic, may be assessed by endoscopy and contrast radiology. A CT scan can be performed if additional information is needed to aid in further clinical decision making. Findings of a stomach in an unusually high position or with an abnormal axis in a patient with acute abdominal pain and vomiting should make one suspect gastric volvulus³⁰. Emergency presentations of hiatal hernia, such as with gastric obstruction or ischemia, may first be decompressed with a nasogastric tube followed by a plain chest radiograph and endoscopy. Excessive investigation in emergency presentation may lead to delay in treatment and



suboptimal outcomes³¹. CT scan may be especially useful in cases of diagnostic dilemma, though in retrospect, the diagnosis is frequently evident on prior imaging³².

Indications for Surgery

Guideline 2

- Repair of a type I hernia in the absence of reflux disease is not necessary (**+++**, **strong**)

The major clinical significance of a Type I hernia is its association with reflux disease. In patients with proven gastroesophageal reflux disease, with or without a sliding hiatal hernia, antireflux surgery is an option for the management of their condition^{33, 34}. The indication for repair of a sliding (Type I) hiatal hernia is gastroesophageal reflux disease. The hernia is not the indication for the procedure, but must be repaired. A fundoplication to address the reflux disease is mandatory²⁰. Outside of this situation, Type I sliding hiatal hernias have been thought to be almost inconsequential and not warranting of themselves surgical repair³⁵, despite a few studies reporting severe symptoms and complications related to these hernias³⁶⁻³⁸. Occasionally, such hernias are thought to produce dysphagia symptoms or rarely gastric ulceration. While these may occur, they are rare, and repair of a Type I hernia is nearly always unnecessary in the absence of gastroesophageal reflux disease.

Guideline 3

- All symptomatic paraesophageal hiatal hernias should be repaired (**++++**, **strong**), particularly those with acute obstructive symptoms or which have undergone volvulus.

Guideline 4

- Routine elective repair of completely asymptomatic paraesophageal hernias may not always be indicated. Consideration for surgery should include the patient's age and comorbidities. (**+++**, **weak**)



Guideline 5

- Acute gastric volvulus requires reduction of the stomach with limited resection if needed. **(++++, strong)**

Many patients with a hiatal hernia are symptomatic¹⁰. However, for many patients these symptoms are only mild and the condition is detected incidentally on a chest radiograph performed for another reason^{8, 39}. In patients with sliding hiatal hernias symptoms are generally attributable to gastroesophageal reflux. Expert opinion suggests that truly asymptomatic paraesophageal hiatal hernias do exist, but are rare. When questioned carefully often symptoms such as post-prandial chest fullness or shortness of breath are present. Heartburn and reflux symptoms are uncommon with paraesophageal hernias.

It is likely that some paraesophageal hiatal hernias develop from smaller hiatal hernias. Others may develop from anatomic changes such as occur with kyphosis and degenerative disc disease in the spine⁴⁰. As more stomach moves up into the thorax, respiratory symptoms may predominate secondary to pulmonary compression and reduction in forced vital capacity^{10, 41}. Recurrent aspiration pneumonia is also possible³⁹. Later, with vascular compromise from volvulus, gastric mucosal ischemia may cause ulceration, bleeding and anemia. Iron deficiency anemia can be seen in up to 50% of patients with a paraesophageal hiatal hernia⁴¹.

Obstructive symptoms range from mild nausea, bloating, or postprandial fullness to acute distress with dysphagia and retching. Pain, often described as a full or heavy feeling in the upper abdomen or as severe postprandial pain is often relieved by vomiting⁴². Dysphagia and postprandial fullness occur secondary to compression of the adjacent esophagus by a progressively expanding herniated stomach and by angulation of the gastroesophageal junction that occurs as the stomach becomes progressively displaced in the chest, and also by volvulus of the stomach as that organ migrates progressively into the chest⁴³.

Very little published information exists regarding the natural course of untreated hiatal hernias. Of the little data which are available, most relate to hernias thought to be at risk of developing acute symptoms, particularly obstruction. Only hernias where the gastric fundus has migrated above the diaphragm, that is, paraesophageal hernias, are at risk of obstruction. There is a suggestion that the risk of progression from asymptomatic to symptomatic paraesophageal hernia is approximately 14% per year^{44, 45}. This information, together with early reports of near universal mortality resulting from these complications, particularly from gastric necrosis, has in the past led to the dictum that all paraesophageal hernias should be repaired electively in suitable surgical candidates^{46, 47}. This is particularly important for patients with symptomatic hernias where the risk of complication is said to be higher⁴⁸. Age should not be a barrier to repair of symptomatic hernias. However, more recent reports have shown that mortality rates for emergency paraesophageal hernias operations are currently much lower than those reported in the last century^{50, 51}. Mortality rates for emergency repair have been reported to be as low as 0 - 5.4%^{45, 52}, though average mortality rates for emergency hiatal hernia surgery are around



17%⁴⁵. Moreover, the risk of developing acute symptoms requiring emergency surgery is probably less than 2% per year^{45, 53-56}.

Decision analysis modeling of contemporary data suggests that routine elective repair of completely asymptomatic paraesophageal hernias may not be indicated⁴⁵; that is, such hernias may be safe to observe and to manage expectantly. This conclusion, based on analysis of 5 studies⁵³⁻⁵⁷, suggests that repair should be reserved for patients with symptoms of gastric outlet obstruction, those with severe gastroesophageal reflux or anemia, and those with possible gastric strangulation. Furthermore, this model suggested that elective laparoscopic hiatal hernia repair in asymptomatic patients might actually decrease the quality-adjusted life expectancy for patients aged 65 years and older. Surgical repair of hernias for the aforementioned respiratory symptoms and symptoms of post-prandial fullness is less well studied.

Strangulation of the stomach can be a consequence of acute gastric volvulus, with resultant, ischemia, necrosis and perforation of the stomach. Treatment includes reduction of the stomach and limited gastric resection in cases of gastric necrosis. The laparoscopic approach can be used in the majority of cases, but conversion to open should be considered for complex problems or when appropriate for the safety of the patient^{58,59}.

Repair of hiatal hernia during bariatric operations

Guideline 6

- During operations for Roux-en-Y gastric bypass, sleeve gastrectomy and the placement of adjustable gastric bands, all detected hiatal hernias should be repaired (**+++**, **weak**)

Hiatal hernias are often detected during the course of a bariatric operation, or other operations at or near the diaphragmatic hiatus. The hernias can be detected by noting “dimpling” anterior to the esophagus, or noting a large hernia sac with contents. Some describe the disappearance with gentle traction of the inflated band calibration balloon up into the mediastinum as being evidence of a hiatal hernia. There are many references in the literature of increased complications, particularly heartburn, after placement of an adjustable gastric band in patients with a hiatal hernia⁶⁰⁻⁶² though this data is neither prospectively collected nor controlled. Because of this association with gastroesophageal reflux symptoms, many now recommend looking for, and repairing hiatal hernias at the time of gastric band insertion^{61, 63}. This advice must be tempered by other reports which show that placement of an adjustable gastric band may relieve reflux symptoms, even without reduction of a hiatal hernia

In a retrospective study of patients undergoing adjustable gastric band placement all sliding hiatal hernias identified intraoperatively were repaired by posterior crural approximation. If a hernia was not evident but there was nonetheless “dimpling” anterior to the esophagus, then an



anterior crural approximating stitch was placed. This study demonstrated a significant reduction in reoperation rates for band prolapse and pouch dilatation when this approach was implemented. The authors' concluded that repairing any detected hiatal hernia during band placement is to be recommended⁶¹.

There are small case series suggesting possible benefits of hiatal hernia repair combined with other types of bariatric surgery, such as gastric bypass⁶⁷⁻⁶⁹ and sleeve gastrectomy⁷⁰⁻⁷².

Predictors of outcome

Guideline 7

- Postoperative nausea and vomiting should be treated aggressively to minimize poor outcomes (**++**, **strong**)

In the early postoperative period, sudden increases in intra-abdominal pressure are thought to predispose to anatomical failure. Also, early postoperative gagging, belching, and vomiting have been suggested to be predisposing factors for anatomical failure and the need for revision⁷³.

Morbidity is substantially higher among elderly patients and those with co-morbidities when compared to younger patients, but with no increase in the recurrence rate. Mortality rate among elderly patients undergoing PEH repair continues to be high following emergency procedures⁷⁴. The mortality is related mainly to pulmonary complications, thromboembolic events and hemorrhage⁷⁵.

Obesity, a significant independent risk factor for development of a hiatal hernia⁷⁶, also increases the rate of hernia recurrence^{77, 78}.

The larger the size of the hiatal hernia, as measured by the hiatal surface area, the more likely the recurrence⁷⁹, particularly if the surface area is greater than 5.6 cm² independent of patient height, weight and BMI⁸⁰. Some authors suggest using mesh crural reinforcement for these large hernias to prevent recurrence⁸¹.

Technical Considerations

Operative approach - transthoracic or transabdominal; laparoscopic or open

Guideline 8



- Hiatal hernias can effectively be repaired by a transabdominal or transthoracic approach (**++++, strong**). The morbidity of a laparoscopic approach is markedly less than that of an open approach (**++, strong**)

Guideline 9

- Laparoscopic hiatal hernia repair is as effective as open transabdominal repair, with a reduced rate of perioperative morbidity and with shorter hospital stays. It is the preferred approach for the majority of hiatal hernias (**++++, strong**)

Large hiatal hernias can be repaired either transabdominally (open or laparoscopic) or via thoracotomy⁸², usually through the left chest. There are no randomized trials directly comparing open transthoracic vs. open transabdominal hiatal hernia repair, and there are no data assessing minimally-invasive thoracic approaches. There is decreased perioperative morbidity and mortality with laparoscopic repair compared to open transthoracic repair^{83, 84}. While the trans-thoracic approach offers excellent visualization of the hiatus and the ability to maximally mobilize the esophagus, expert opinion suggests that the morbidity and prolonged recovery associated with this approach have rendered it obsolete except in rare circumstances. Nonetheless, one potential advantage of transthoracic route is ability for more extensive esophageal mobilization⁸⁵, however many transthoracic series have a higher percentage of patients requiring Collis gastroplasty compared to laparoscopic series⁸⁶. The standard for repair today is a laparoscopic approach. Critics of the laparoscopic series cite false overestimation of intra-abdominal esophageal length due to diaphragmatic elevation from pneumoperitoneum⁸⁷ as a limitation of the approach. Further, the complexity of a laparoscopic Collis gastroplasty prohibits its use in some cases. Transabdominal open repair may be most appropriate in an emergency where there is peritoneal contamination or gastric necrosis⁵².

Geha *et al*⁸⁸ reported follow-up for 100 consecutive patients undergoing open repair. In their experience of the 18 patients who underwent transthoracic repair, two patients required subsequent transabdominal repair for organoaxial volvulus. In remaining patients a transabdominal repair was done with frequent use of gastropexy. Fundoplication was done only selectively and Collis gastroplasty done only in 2% of the patients. There were no recurrences in the entire cohort. Other contemporary authors have compared transabdominal to transthoracic access for PEH repair, and have concluded that outcomes are equivalent⁸⁹.

Laparoscopic hiatal hernia repair results in less postoperative pain compared with the open approach. The smaller incisions of minimally-invasive surgery are less likely to be complicated by incisional hernias and wound infection. Postoperative respiratory complications are reduced⁹⁰. Results from multiple studies are similar, with shorter hospital stay and less morbidity



resulting from the minimally invasive approach^{55, 91-101}. Recurrence rates are similar.

Open conversion is occasionally necessary for reasons such as bleeding, splenic injury or dense adhesions, and it is important that surgeons taking these on as laparoscopic procedures are comfortable with an open repair should conversion become necessary.

Hernia sac excision

Guideline 10

- During paraesophageal hiatal hernia repair the hernia sac should be dissected away from mediastinal structures (**++**, **strong**), and then preferably excised (**++**, **weak**)

Sac dissection during paraesophageal hernia repair is thought to release the tethering of the esophagus, to facilitate intraoperative reduction of the hernia and to decrease early recurrence, as well as protecting the esophagus from iatrogenic damage^{95, 102}. Prior to addressing the sac on the right side of the esophagus, the left gastric vessels should be reduced into the abdomen to prevent injury. Subsequent excision of the peritoneal hernia sac is performed routinely in most recent reports^{12, 103}, but not all¹⁰⁴. There is some evidence to support this practice¹⁰⁵, though the single case series examining the issue had marked variation in the type of hiatal hernia, operative technique and was early in the surgeons' learning curve. Five of 25 operations without sac excision suffered hernia recurrence during a 38 month follow-up period, all between 1-8 weeks following surgery. No recurrences were reported at 15 months follow-up for the 30 patients whose paraesophageal hernia repair procedure included hernia sac excision. The authors' conclusion was that sac excision is "an essential" step in laparoscopic paraesophageal hernia repair. Studies examining sac excision which actually specify hernia type, fail to include Type I hernia.

Occasionally sac excision can be quite difficult, particularly in large hiatal hernias. Some advocate that under this circumstance, disconnection of the sac from the crura and sac dissection only is performed, but sac excision is not required^{102, 106}. Sac excision in such circumstances might predispose to vagal injury. When this technique is compared to complete excision in retrospective but underpowered analyses, leaving of the sac *in situ* results in trends towards higher recurrence, but no statistical difference has been seen¹⁰⁷. Expert opinion suggests that if the sac is not to be completely excised then at least partial sac excision should be performed to allow the fundoplication to be performed without excess bulk by a large residual sac.

Reinforced repair



Guideline 11

- The use of mesh for reinforcement of large hiatal hernia repairs leads to decreased short term recurrence rates (**+++**, **strong**)

Guideline 12

- There is inadequate long-term data on which to base a recommendation either for or against the use of mesh at the hiatus

Primary sutured crural repair has been the mainstay of practice for many years, but objective follow-up has suggested very high recurrence rates of 42% and higher after laparoscopic paraesophageal hernia repair^{108, 109}. This has prompted many authors to advocate that the crural repair be reinforced. The ideal mesh and technique are unknown at this point. Though some novel hiatal reinforcement techniques have been developed, such as using the ligamentum teres¹¹⁰ or left lobe of the liver¹¹¹ for this purpose, most reinforced repairs use some form of mesh. Most commonly the mesh is applied in an on-lay fashion after primary crural closure. A variation, which is similarly considered as a reinforced crural approximation, is the use of pledgets to buttress the primary sutured hiatal repair¹¹². In some cases mesh has been used as an interposition or bridge when crural approximation is not possible¹¹³. In the rare occasion when the crus cannot be primarily approximated, various techniques using native or prosthetic material have been described, as have techniques for crural relaxing incisions to allow primary crural closure in patients with large defects^{87, 114-117}.

Three randomized-controlled trials (RCTs), summarized in Table 1, have examined the question of whether mesh repair is beneficial. The first¹¹⁸ specifically studied patients with a giant hiatal defect, defined as greater than 8cm crural separation. The type of hernia was not specified. With a mean follow-up of 3.3 years, radiographic recurrence was 22% in the primary sutured repair group, all of which occurred within the first 6 months postoperatively, and zero in a group which had on-lay PTFE reinforcement of the crural repair. All recurrences were symptomatic, though the symptoms are not described. The PTFE mesh encircled the esophagus. No mesh related complications during the study period were reported.

The second RCT¹¹⁹ did not examine hiatal hernias *per se*, but included patients who underwent full esophageal mobilization at the diaphragmatic hiatus in the course of a fundoplication for gastroesophageal reflux disease. Approximately half of the studied patients had a hernia defect greater than 5cm. A rectangular piece of polypropylene mesh was placed in on-lay fashion over the crural repair. Of patients with a primary repair of the crura, 26% developed a subsequent hiatal hernia, as compared to only 8% of patients receiving the mesh.



The third RCT¹⁷ trial included hernia defects 5cm or greater and randomized patients to either primary repair or an on-lay application of a 'U'-shaped porcine small intestinal submucosal biologic prosthesis. In the control group, 90% of patients had a Type III or IV hernia compared to 84% of patients in the treatment arm. A significant number of patients were not followed-up according to the study protocol. Many interim analyses were performed and it is unclear as to whether these analyses were accounted for in either initial sample size determination or interim stopping rules¹²⁰. Radiological recurrences were reported in 24% (n=12) of patients with primary repair vs. 9% (n=4) in the biologic prosthesis group (p=0.04) at 6 months. No mesh-related complication was reported. Follow-up data from this study have recently been published and reported equal recurrence rates in both arms. At four years of follow-up there was no improvement in recurrence rates with the use of mesh (both arms showed recurrence rates of >50%), nor in clinical symptoms¹²¹. There was a significant drop-out rate during this follow-up study, and not all patients completing the study underwent radiographic evaluation for recurrence. More patients from the mesh-repair group failed to be completely followed-up compared to the primary repair control group, introducing an element of bias into the conclusions.

In summary, short-term results of these three randomized controlled trials were supportive of reinforced hiatoplasty, but this has not been borne out with longer-term results. Additional evidence is required to better establish the safety and long term outcomes of mesh use at the hiatus.

Table 1: Prospective Randomized Controlled Studies evaluating recurrence of PEH after mesh repair

	Frantzides <i>et al.</i> 2002	Granderath <i>et al.</i> 2005	Oelschlager <i>et al.</i> 2011
n=	72	100	60†
Inclusion criteria	Hiatal defect > 8cm	Symptomatic gastroesophageal reflux	Hiatal defect > 5cm
Diagnosis of hiatal hernia	EGD and barium	EGD and at laparoscopy‡	Barium esophagram
PEH types included	I, II, III, IV	Not described	II, III, IV
Mesh	Keyhole PTFE	Rectangular polypropylene	U-shaped 4-ply porcine small intestinal submucosa
Mesh fixation	Staples	Sutured	Sutured
Fundoplication	360° posterior	360° posterior	360° posterior
Follow-up (mean ± SD, years)	3.3 ± 1.7	1	4.8
Diagnosis of recurrence	Barium esophagram	Barium esophagram	Barium esophagram
Recurrence			

**Table 1: Prospective Randomized Controlled Studies evaluating recurrence of PEH after mesh repair**

	Frantzides <i>et al.</i> 2002	Granderath <i>et al.</i> 2005	Oelschlager <i>et al.</i> 2011
Control arm (n)	22% (8)*	26% (13)	59% (20)
Treatment arm (n)	0 (0)	8% (4)	54% (14)
p=	< 0.006	< 0.001	0.7
Timing of recurrence	All within 6 months	Not described	Within 5 years
Mesh-related complications	None	None	None

† Only 60 patients completed follow-up including having a barium esophagram.

‡ 90% of each arm had a preoperative endoscopically-diagnosed hiatal hernia.

At operation, 40% of the control arm and 42% of the mesh treatment arm had a hernia defect > 5cm.

* 5 patients (14%) underwent reoperation

Many case series exist on the topic, and the majority suggest benefit with mesh¹²²⁻¹²⁸. However, there are a few which question the use of meshed repair¹²⁹⁻¹³².

Extrapolation from the use of mesh in abdominal wall hernias would suggest that the use of such products to bridge a defect, that is span the crural defect without primary crural approximation, is unlikely to be successful^{116, 117, 133}.

Long-term safety related to the type of mesh used and placement technique is important, with many similarities being drawn in the literature to the Angelchik prosthesis used as an antireflux barrier in past decades which was found to cause frequent erosions into the esophageal lumen¹³⁴. A limitation of the available data is the lack of long-term follow-up mesh implantation. Most reports are small case series with a median follow-up of less than 3 years. Complications are reported with all types of mesh, both synthetic and biologic, as well as of varying mesh geometry^{131, 132, 135}. Although mesh erosion is the most feared complication¹³⁵⁻¹³⁷, other complications also can occur, such as esophageal stenosis, pericardial tamponade¹³⁸ and effusion. Expert opinion suggests that synthetic mesh when placed as a bridge is more likely to have direct contact with the oesophagus and as a result is probably associated with erosion. Bridging synthetic mesh should therefore be avoided.

The meshes have been fixed by using a variety of different techniques, including various glues, tacks and sutures^{104, 139}. Inadequate evidence exists for a recommendation to be made regarding optimal fixation techniques, although care should be taken that fixation methods (particularly tacks) do not breach the aorta or pericardium when applied low on the left crus or near the apex of the crura anteriorly.

Fundoplication

Guideline 13



- A fundoplication must be performed during repair of a sliding type hiatal hernia to address reflux. A fundoplication is also important during paraesophageal hernia repair. **(++, weak)**

Guideline 14

- In the absence of achalasia, tailoring of the fundoplication to preoperative manometric data may not be necessary **(++, weak)**

The majority of reports of paraesophageal hiatal hernia repair in the recent literature describe the performance of a fundoplication as a step of the repair. This is thought to aid in prevention of postoperative gastroesophageal reflux and to buttress the repair to prevent recurrence^{25, 140, 141}. Moreover, there is a suggestion that the majority of patients with paraesophageal hernias have an incompetent lower esophageal sphincter¹⁴². Extensive hiatal dissection might also potentiate reflux. There is however no high-level evidence to support this practice of routine fundoplication; case reports form the majority of the evidence base and the conclusions are mixed. Two generally representative studies are described in illustration:

One recent case-controlled study¹⁴³ divided 46 patient undergoing laparoscopic paraesophageal hiatal hernia repair into two equal groups with and without fundoplication. The complete 360-degree fundoplications were performed over a 56F bougie and generally without division of the short gastric vessels. Findings were of increased dysphagia with fundoplication, and of reflux symptoms in the group without fundoplication. The authors concluded that routine fundoplication should be avoided.

A separate retrospective study comparing 40 patients undergoing fundoplication for both reflux disease and hiatal hernia showed no dysphagia with fundoplication in the group of patients with paraesophageal hernia¹⁴⁴. The authors concluded that there exists a benefit in reflux symptoms with the routine use of a fundoplication as an addition to the repair of the hiatus.

Hernia recurrence rates after fundoplication are not satisfactorily addressed in the current body of literature.

There is little information available in the current literature about tailoring the fundoplication during hiatal hernia repair, though preoperative manometric data has been used to guide the degree of wrap⁸. The [SAGES Guidelines for surgical treatment of gastroesophageal reflux disease](#)²⁰ found that a tailored approach to fundoplication is unwarranted in the surgical treatment of reflux, though this document did not examine the case of hiatal hernias.



Short esophagus

Guideline 15

- A necessary step of hiatal hernia repair is to return the gastroesophageal junction to an infradiaphragmatic position (**+++**, **strong**)

Guideline 16

- At the completion of the hiatal repair, the intra-abdominal esophagus should measure at least 2 - 3cm in length to decrease the chance of recurrence (**++**, **weak**). This length can be achieved by combinations of mediastinal dissection of the esophagus and/ or gastroplasty (**++++**, **strong**)

Hiatal hernia recurrence can be reduced by extensive mediastinal esophageal mobilization to bring the gastroesophageal junction at least 2 - 3 cm into the abdomen without tension^{10, 22, 145, 146}. High mediastinal dissection may reduce the need for an esophageal lengthening procedure¹⁴⁷. If mobilization fails to bring the gastroesophageal junction into the abdomen, an esophageal lengthening procedure should be performed^{9, 43}. The addition of a Collis gastroplasty is suggested in several studies when a short esophagus is encountered after reduction of the hernia, dissection of the hernia sac and mobilization in the mediastinum^{10, 148}. Some authors report very high utilization rates of Collis gastroplasty for primary hiatal hernia repair, particularly of Types III and IV, some even using this procedure for the majority of patients. These retrospective reviews usually describe low recurrence rates^{86, 149}. The gastric neo-esophagus formed by a Collis gastroplasty does not exhibit peristaltic activity like the native esophagus, and therefore dysphagia is a potential problem¹⁵⁰. Also, performance of a gastroplasty increased the rate of postoperative leaks in some studies¹⁵¹. There is evidence that a Collis gastroplasty is quite safe to perform if a foreshortened esophagus is encountered, though perioperative complication rates are higher than when a gastroplasty is not performed. Rates of postoperative dysphagia after Collis gastroplasty vary between reports (Table 3).

A recent paper describing outcome of 166 patients undergoing either reoperative antireflux surgery or hiatal hernia repair evaluated vagus nerve division in the setting of a short esophagus¹⁵². It was proposed that a vagotomy is an alternative to Collis gastroplasty when extensive mobilization of the esophagus fails to provide adequate esophageal length. The authors did not find any significant difference between a control group and the vagotomized group in terms of symptoms like abdominal pain, bloating, diarrhea, or early satiety. No patient



in this study required subsequent surgical intervention for gastric outlet obstruction. Vagotomy for esophageal lengthening cannot be recommended based on this one study alone.

Table 3: Evaluation of the management of short esophagus

	Johnson 1998	Gastal 1999	Mittal 2000	Maziak 1998	Oelschlager 2008	Garg 2009	Legner 2010
n=	9	37	10	75 gastroplasties of 94 total	17 vagotomies in 50 PEH repairs	85(75% primary)	16
Study type	Retrospective	Retrospective	Retrospective	Retrospective	Retrospective	Retrospective	Retrospective
Inclusion criteria	< 2cm intra-abdominal esophagus	NR	< 2cm intra-abdominal esophagus (changed to < 3cm later in study)	Large hiatal hernia (sliding and paraesophageal)	< 3cm intra-abdominal esophagus	< 3cm intra-abdominal esophagus	Reoperative surgery only < 2cm intra-abdominal esophagus
Approach	Laparoscopic	Open transthoracic	Laparoscopic repair, transthoracic Collis	97% open transthoracic, 3% open transabdominal	Laparoscopic	52% transthoracic, 48% laparoscopic	44% transabdominal and 56% transthoracic
Lengthening procedure	Collis	Collis	Collis over 46F bougie	Collis over 48F bougie	Vagotomy	Collis	Collis
Antireflux procedure	Nissen	Belsey	Nissen	97% Belsey Mk IV, % Nissen	Nissen or Toupet	Nissen or Toupet	Nissen(81%), Toupet and Belsey
Follow-up	1 year	NR	NR	Mean 93.6mo	Median 19mo	Median 49mo	Mean 21.9mo
Dysphagia							
Preoperative	22%	NR	NR	48%		57%	NR
Postoperative	11%	14%	NR	11%	No difference to control	28%* (7% of total required dilatation)	NR
Heartburn							
Preoperative	44%	NR	NR	83%		76%	NR
Postoperative	11%	NR	NR	NR	No difference to control	24%*	NR
Recurrence	NR	NR	NR	NR	NR	NR	
Complications	None	22%	NR	2% mortality	None	1.2%	No mortality



Table 3: Evaluation of the management of short esophagus

	Johnson 1998	Gastal 1999	Mittal 2000	Maziak 1998	Oelschlager 2008	Garg 2009	Legner 2010
Results				5.3% leak		mortality 1.2% perforation	18.8% leak
Recommendation	Collis gastroplasty is safe	Hiatal hernia < 5cm of an esophageal stricture predicts need for gastroplasty	Short esophagus is best predicted by endoscopy; manometry and contrast studies are inaccurate	Short esophagus requires a lengthening procedure	Vagotomy is an alternative to a Collis gastroplasty	Collis is required for inadequate intra-abdominal esophageal length	With preoperative dysphagia, Collis gastroplasty increases risk for postoperative dysphagia

NR = not reported

Gastropexy

Guideline 17

- Gastropexy may safely be used in addition to hiatal repair (**++++, strong**)

Guideline 18

- Gastrostomy tube insertion may facilitate postoperative care in selected patients (**++, strong**)

Guideline 19

- Hernia reduction with gastropexy alone and no hiatal repair may be a safe alternative in high-risk patients but may be associated with high recurrence rates (**++, weak**). Formal repair is preferred (**++++, strong**)



The placement of a gastrostomy tube is often used to both provide fixation of the anterior stomach to the abdominal wall and to aid in post-operative venting of the stomach in cases of delayed gastric emptying. One of the first studies promoting an anterior gastropexy to reduce the recurrence rate after laparoscopic hiatal hernia repair described in a prospective series of 28 patients a repair with reduction of the hernia, sac excision, crural repair, anti-reflux procedure and routine anterior gastropexy¹⁵⁶. No Type I hernias were included. No recurrences were reported in up to 2 years of follow-up evaluation. This finding has been supported by others; a recent study of 89 patients with large hiatal hernias undergoing laparoscopic repair concluded that the addition of a anterior gastropexy significantly reduced recurrent hernias¹⁰³. Other reports concluded the opposite. Medium-term outcome in 116 patients having laparoscopic paraesophageal hernia repair¹⁵⁷, with and without gastropexy, found no significant difference in recurrence rate.

The obese population has been separately studied; a report of a series of hiatal hernia repairs compared a group having the addition of a sleeve gastrectomy to the repair to another group having the addition of gastrostomy tube gastropexy to the repair. Medium-term outcomes were inferior with hernia repair and gastropexy⁷¹.

Liberal gastrostomy tube placement for decompression and enteral access is promoted in a recent retrospective study after repair of an intrathoracic stomach. Sixty percent of the patients in this series had a gastrostomy tube placed intraoperatively which was required postoperatively for decompression and/or giving medications⁶⁹.

Some authors have described hernia reduction and gastropexy alone without cruroplasty or sac excision^{158, 159}, particularly in high-risk symptomatic patients. Mortality and morbidity were low, but radiological recurrence was 22% at 3 months. Results are inferior to formal repair techniques and so gastropexy alone should not be the aim of surgery but rather a fallback option.

Postoperative management

Medical management

Guideline 20

- With early postoperative dysphagia common, attention should be paid to adequate caloric and nutritional intake (**+**, **strong**)

Sudden increases in intra-abdominal pressure are thought to predispose the patient to early anatomical failure of the fundoplication and the hiatal hernia repair⁷³. It is suggested that early postoperative gagging, belching, and vomiting are predisposing factors for anatomical failure



and the need for revision⁷³, and therefore should mandate early and aggressive therapy if they occur. Gastric distension should be recognized early as it can be potentially dangerous in the immediate postoperative phase¹⁶⁰, and can be treated successfully by the placement of a nasogastric tube⁶⁹ or, in cases where an intraoperative gastrostomy tube was placed, by venting the stomach through this tube.

Early postoperative dysphagia rates are up to 50% and the general recommendation is for slow advancement of diet from liquids to solids. Attention should be paid to adequate caloric and nutritional intake in the postoperative period. Expert opinion suggests that most patients will lose 10-15 pounds (4.5 – 7 kg) with laparoscopic fundoplication and hernia repair followed by a graduated diet from liquids to soft solids. If dysphagia persists or weight loss occurs of 20 or more pounds (9 kg) evaluation and intervention for the dysphagia should be considered.

Postoperative contrast studies

Guideline 21

- Routine postoperative contrast studies are not necessary in asymptomatic patients (**+++**, **strong**)

There are no studies supporting routine contrast imaging after hiatal hernia repair. If patients show symptoms of severe dysphagia or the possibility of a leak or perforation, a contrast study is indicated. Routine radiographic follow-up shows a greater incidence of recurrence than symptomatic follow-up alone⁴, but because most recurrences are small and asymptomatic¹⁶¹, many suggest routine radiographic follow-up is not indicated.

Revisional surgery

Guideline 22

- Revisional surgery can safely be undertaken laparoscopically by experienced surgeons (**+++**, **strong**)

Recurrent hiatal hernia repair is indicated when the symptoms match anatomical findings⁴³. The revisional surgery can often be completed laparoscopically in experienced hands^{43, 89}. Any previous fundoplication should be taken down in its entirety, the right and left crura exposed,



and the hernia sac excised. Attention should be directed to ensuring adequate intra-abdominal esophageal length⁸⁹. The success of laparoscopic revisional hiatal hernia surgery approaches that of the primary repair¹⁶², though there remains an increase in recurrence rates. Mesh can be safely used in revisional surgery¹⁶³, though there is inadequate and underpowered data to support its use.

Pediatric considerations

Pediatric Guidelines

Indications for surgery

23. Symptomatic hiatal hernias in children should be surgically repaired (**++**, **weak**)
24. A laparoscopic approach in children is feasible. Age or size of the hernia should not be an upfront contraindication to laparoscopy (**++**, **weak**)

Indications for surgery - pediatric

Hiatal hernias in children may be congenital or acquired. The incidence in this age group is low, and subsequently there is a lack of high-quality data for management in the pediatric population. Genetic factors such as familial inheritance¹⁶⁴, right isomerism¹⁶⁵, Marfan syndrome¹⁶⁶, and collagen type III alpha I¹⁶⁷ may play a role, although most cases are sporadic. Children with a hiatal hernia and symptomatic gastroesophageal reflux have been shown to exhibit high failure rates of conservative management in a prospective trial of 718 patients¹⁶⁸. Therefore, surgical repair with concomitant fundoplication is advised in this cohort.

Clinically, children with hiatal hernias may be asymptomatic, or present with reflux symptoms including vomiting, aspiration, acute life-threatening events, respiratory distress, recurrent pneumonia, feeding problems, failure to thrive, melena, anemia, and gastric volvulus in rare cases¹⁶⁸⁻¹⁷⁰. Occasionally, they are diagnosed on chest radiographs performed for other reasons¹⁶⁹. An upper GI contrast study is the most efficient and reliable diagnostic test to delineate the gastroesophageal anatomy¹⁶⁶ and to rule out other causes of vomiting such as malrotation. Esphagoscopy is helpful to evaluate for esophagitis and pH-probe allows quantitative assessment for gastroesophageal reflux, which is present in over half of children with hiatal hernias¹⁷¹. In some cases, hiatal hernias diagnosed in infancy may spontaneously mature and resolve. A 20 to 40 year follow-up study of 118 patients with hiatal hernia in infancy showed that the hernia persisted into adulthood in 53% of patients treated nonsurgically, and that 17 of 24 patients who had undergone surgery as a child had a hiatal hernia on upper GI contrast study as adults¹⁷². Heartburn was common in both the conservatively and surgically managed groups, and one patient in each group developed Barrett's esophagus



Although transthoracic and transabdominal repair has been described, the latter is preferred by most pediatric surgeons¹⁷¹.

Pediatric Guidelines

Technical considerations

25. Gastroesophageal reflux in pediatric patients with a hiatal hernia should be addressed by a concomitant anti-reflux procedure (**++**, **weak**)
26. The current standard of care in children is either excision of the hernia sac or disconnection of the sac from the crura (**+++**, **weak**)
27. To lower the risk of postoperative paraesophageal hernia after fundoplication in the pediatric population, minimal hiatal dissection should be performed (**++**, **weak**)
28. Plication of the esophagus to the crura may decrease recurrence in children (**+**, **weak**)

Technical considerations – pediatric

The majority of reports include an anti-reflux procedure in patients with preoperative gastroesophageal reflux¹⁷¹. In fact, 12 of 20 children developed recurrent reflux symptoms after a simple hiatal repair without an antireflux procedure in a historic cohort of one study¹⁷⁰. Laparoscopic repair of even large paraesophageal hernias is feasible in the pediatric population^{173, 174}. Most reports advocate resection^{166, 169, 171, 173, 175} or incision¹⁷⁴ of the hernia sac. Laparoscopic Collis gastroplasty and Nissen fundoplication has been described for severe recurrent reflux in patients with esophageal atresia, gastroesophageal reflux, and recurrent hiatal hernia as young as 5 years of age¹⁵¹. In this series, one out of 6 patients had a gastric perforation that required open re-exploration. Hence this approach should be individualized to select patients where standard treatment has failed.

The risk of recurrence after paraesophageal hiatal hernia repair and fundoplication is higher in children who exhibit preoperative gagging, retching, and slow gastric emptying¹⁷⁵. The risk of recurrence was shown to be lower if the esophagus was plicated to the crus in one study of 464 children¹⁷⁵. Plication in this study, however, was associated with a higher incidence of other perioperative complications. Minimal as opposed to extensive hiatal dissection during the primary anti-reflux operation also decreased the risk of postoperative paraesophageal hernia from 30% to 7.8% in a randomized trial of 177 pediatric patients¹⁷⁶.

Summary



Guidelines for the Management of Hiatal Hernia

Diagnosis

1. Hiatal hernia can be diagnosed by various modalities. Only investigations which will alter the clinical management of the patient should be performed (**+++**, **strong**)

Indications for Surgery

2. Repair of a type I hernia in the absence of reflux disease is not necessary (**+++**, **strong**)
3. All symptomatic paraesophageal hiatal hernias should be repaired (**++++**, **strong**), particularly those with acute obstructive symptoms or which have undergone volvulus.
4. Routine elective repair of completely asymptomatic paraesophageal hernias may not always be indicated. Consideration for surgery should include the patient's age and comorbidities. (**+++**, **weak**)
5. Acute gastric volvulus requires reduction of the stomach with limited resection if needed. (**++++**, **strong**)

Repair of Hiatal Hernia During Bariatric Operations

6. During operations for Roux-en-Y gastric bypass, sleeve gastrectomy and the placement of adjustable gastric bands, all detected hiatal hernias should be repaired (**+++**, **weak**)

Predictors of Outcomes

7. Postoperative nausea and vomiting should be treated aggressively to minimize poor outcomes (**++**, **strong**)

Technical Considerations

8. Hiatal hernias can effectively be repaired by a transabdominal or transthoracic approach (**++++**, **strong**). The morbidity of a laparoscopic approach is markedly less than that of an open approach (**++**, **strong**)
9. Laparoscopic hiatal hernia repair is as effective as open transabdominal repair, with a reduced rate of perioperative morbidity and with shorter hospital stays. It is the preferred approach for the majority of hiatal hernias (**++++**, **strong**)
10. During paraesophageal hiatal hernia repair the hernia sac should be dissected away from mediastinal structures (**++**, **strong**), and then preferably excised (**++**, **weak**)
11. The use of mesh for reinforcement of large hiatal hernia repairs leads to decreased short term recurrence rates (**+++**, **strong**)
12. There is inadequate long-term data on which to base a recommendation either for or against the use of mesh at the hiatus
13. A fundoplication must be performed during repair of a sliding type hiatal hernia to address reflux. A fundoplication is also important during paraesophageal hernia repair. (**++**, **weak**)
14. In the absence of achalasia, tailoring of the fundoplication to preoperative manometric



data may not be necessary (**++**, **weak**)

15. A necessary step of hiatal hernia repair is to return the gastroesophageal junction to an infradiaphragmatic position (**+++**, **strong**)
16. At the completion of the hiatal repair, the intra-abdominal esophagus should measure at least 2 - 3cm in length to decrease the chance of recurrence (**++**, **weak**). This length can be achieved by combinations of mediastinal dissection of the esophagus and/or gastroplasty (**++++**, **strong**)
17. Gastropexy may safely be used in addition to hiatal repair (**++++**, **strong**)
18. Gastrostomy tube insertion may facilitate postoperative care in selected patients (**++**, **strong**)
19. Hernia reduction with gastropexy alone and no hiatal repair may be a safe alternative in high-risk patients but may be associated with high recurrence rates (**++**, **weak**). Formal repair is preferred (**++++**, **strong**)

Postoperative Management

20. With early postoperative dysphagia common, attention should be paid to adequate caloric and nutritional intake (**+**, **strong**)
21. Routine postoperative contrast studies are not necessary in asymptomatic patients (**+++**, **strong**)

Revisional Surgery

22. Revisional surgery can safely be undertaken laparoscopically by experienced surgeons (**+++**, **strong**)

Pediatric Considerations

Indications for surgery

23. Symptomatic hiatal hernias in children should be surgically repaired (**++**, **weak**)
24. A laparoscopic approach in children is feasible. Age or size of the hernia should not be an upfront contraindication to laparoscopy (**++**, **weak**)

Technical considerations

25. Gastroesophageal reflux in pediatric patients with a hiatal hernia should be addressed by a concomitant anti-reflux procedure (**++**, **weak**)
26. The current standard of care in children is either excision of the hernia sac or disconnection of the sac from the crura (**+++**, **weak**)
27. To lower the risk of postoperative paraesophageal hernia after fundoplication in the pediatric population, minimal hiatal dissection should be performed (**++**, **weak**)
28. Plication of the esophagus to the crura may decrease recurrence in children (**+**, **weak**)



Table 1: GRADE system for rating the quality of evidence for SAGES guidelines

Quality of Evidence	Definition	Symbol Used
High quality	Further research is very unlikely to alter confidence in the estimate of impact	++++
Moderate quality	Further research is likely to alter confidence in the estimate of impact and may change the estimate	+++
Low quality	Further research is very likely to alter confidence in the estimate of impact and is likely to change the estimate	++
Very low quality	Any estimate of impact is uncertain	?

GRADE recommendations based on the quality of evidence for SAGES guidelines

Strong	It is very certain that benefit exceeds risk for the option considered
Weak	Risk and benefit well balanced, patients and providers faced with differing clinical situations likely would make different choices, or benefits available but not certain regarding the option considered

Adapted from Guyatt *et al***Appendix 1**

This document was prepared and revised by the SAGES Guidelines Committee:

Geoffrey P Kohn MBBS MSurg

Joerg Zehetner MD

Raymond R Price MD



Ziad T Awad MD

Sumeet K Mittal MD

William S Richardson MD

Dimitrios Stefanidis MD PhD

Robert D Fanelli MD

Robert A. Andrews, MD Goffredo O. Arena, MD Edward D. Auyang, MD Simon Bergman, MD Patrice R. Carter, MD Ronald Hanson Clements, MD Giovanni Dapri, MD Elias Darido, MD Teresa Catherine deBeche-Adams, MD Steven R. DeMeester, MD David Bryan Earle, MD David S. Edelman, MD Erika K. Fellingner, MD Shannon A. Fraser, MD Jeffrey A. Genaw, MD Melanie Goldfarb, MD Stephen P. Haggerty, MD Celeste M. Hollands, MD William Borden Hooks III, MD William W. Hope, MD Ifeoma Jacqueline Igboeli, MD Lisa R. Martin Hawver, MD Daniel T. McKenna, MD Erica A. Moran, MD David W. Overby, MD Thomas P. Rauth, MD Arthur Lee Rawlings, MD Kurt E. Roberts, MD Alexander Steven Rosemurgy, MD John Scott Roth, MD Alan A. Saber, MD Shean Satgunam, MD Tejinder Paul Singh, MD Bala Gangadhara Reddy Thatigotla, MRCSEd Marc Zerey, MD

It was reviewed and approved by the Board of Governors of the Society of American Gastrointestinal and Endoscopic Surgeons (SAGES)

For more information, please contact:

Society of American Gastrointestinal and Endoscopic Surgeons (SAGES)
11300 West Olympic Blvd., Suite 600
Los Angeles, CA 90064
Phone: (310) 437-0544
Fax: (310) 437-0585
E-mail: publications@sages.org
<http://www.sages.org/>

Appendix 2: Medline Search Strategy February 2011

Search **(#3) OR (#4) OR (#5)**
OR (#6) OR (#8) OR (#9)

[#11](#)

[564](#)

Search **(#3) OR (#4) OR (#5)**
OR (#6) OR (#7) OR (#9)

[#10](#)

[392](#)

Search **#1** Limits: **Humans,**
Consensus Development



#9	Conference, Consensus Development Conference, NIH, Guideline	1
	Search #1 Limits: Humans, published in the last 10 years	
#8		475
	Search #1 Limits: Humans, published in the last 5 years	
#7		257
	Search #1 Limits: Humans, Clinical Trial	
#6		57
	Search #1 Limits: Humans, Meta-Analysis, Review	
#5		117
	Search #1 Limits: Humans, Randomized Controlled Trial	
#4		17
	Search #1 Limits: Humans, Systematic Reviews	
#3		16
	Search #1 Limits: Humans	
#2		1449
	Search (" Hernia, Hiatal/surgery ") [Mesh] OR	
#1	"Hernia, Hiatal/therapy" [Mesh])	1486

Pediatric-specific search February 2013

#2	Search #1 Limits: Humans	
	500	
#1	Search (" Hiatal hernia in Children ")	530

References



1. Guyatt GH, Oxman AD, Vist GE, Kunz R, Falck-Ytter Y, Alonso-Coello P, Schunemann HJ (2008) GRADE: an emerging consensus on rating quality of evidence and strength of recommendations. *BMJ* 336:924-926
2. SAGES The Definitions Document: A Reference for Use of SAGES Guidelines.
3. Altorki NK, Yankelevitz D, Skinner DB (1998) Massive hiatal hernias: the anatomic basis of repair. *J Thorac Cardiovasc Surg* 115:828-835
4. Andujar JJ, Pappasavas PK, Birdas T, Robke J, Raftopoulos Y, Gagne DJ, Caushaj PF, Landreneau RJ, Keenan RJ (2004) Laparoscopic repair of large paraesophageal hernia is associated with a low incidence of recurrence and reoperation. *Surg Endosc* 18:444-447
5. Barrett NR (1954) Hiatus hernia: a review of some controversial points. *Br J Surg* 42:231-243
6. Kavic SM, Segan RD, George IM, Turner PL, Roth JS, Park A (2006) Classification of hiatal hernias using dynamic three-dimensional reconstruction. *Surgical innovation* 13:49-52
7. Hutter MM, Rattner DW (2007) Paraesophageal and other complex diaphragmatic hernias. In: Yeo CJ (ed) *Shackelford's Surgery of the Alimentary Tract* Saunders Elsevier, Philadelphia, pp 549-562
8. Landreneau RJ, Del Pino M, Santos R (2005) Management of paraesophageal hernias. *The Surgical clinics of North America* 85:411-432
9. Morino M, Giaccone C, Pellegrino L, Rebecchi F (2006) Laparoscopic management of giant hiatal hernia: factors influencing long-term outcome. *Surg Endosc* 20:1011-1016
10. Awais O, Luketich JD (2009) Management of giant paraesophageal hernia. *Minerva Chir* 64:159-168
11. Little VR, Buenaventura PO, Luketich JD (2001) Laparoscopic repair of giant paraesophageal hernia. *Adv Surg* 35:21-38
12. Mitiek MO, Andrade RS (2010) Giant hiatal hernia. *Ann Thorac Surg* 89:S2168-2173
13. Curci JA, Melman LM, Thompson RW, Soper NJ, Matthews BD (2008) Elastic fiber depletion in the supporting ligaments of the gastroesophageal junction: a structural basis for the development of hiatal hernia. *J Am Coll Surg* 207:191-196
14. Baglaj SM, Noblett HR (1999) Paraesophageal hernia in children: familial occurrence and review of the literature. *Pediatric surgery international* 15:85-87
15. Hazebroek EJ, Koak Y, Berry H, Leibman S, Smith GS (2009) Critical evaluation of a novel DualMesh repair for large hiatal hernias. *Surg Endosc* 23:193-196



16. Parameswaran R, Ali A, Velmurugan S, Adjepong SE, Sigurdsson A (2006) Laparoscopic repair of large paraesophageal hiatus hernia: quality of life and durability. *Surg Endosc* 20:1221-1224
17. Oelschlager BK, Pellegrini CA, Hunter J, Soper N, Brunt M, Sheppard B, Jobe B, Polissar N, Mitsumori L, Nelson J, Swanstrom L (2006) Biologic prosthesis reduces recurrence after laparoscopic paraesophageal hernia repair: a multicenter, prospective, randomized trial. *Ann Surg* 244:481-490
18. White BC, Jeansonne LO, Morgenthal CB, Zagorski S, Davis SS, Smith CD, Lin E (2008) Do recurrences after paraesophageal hernia repair matter? : Ten-year follow-up after laparoscopic repair. *Surg Endosc* 22:1107-1111
19. Cardile AP, Heppner DS (2011) Gastric volvulus, Borchardt's Triad, and Endoscopy: A Rare Twist. *Hawaii Med J* 70:80-82
20. Stefanidis D, Hope WW, Kohn GP, Reardon PR, Richardson WS, Fanelli RD (2010) Guidelines for surgical treatment of gastroesophageal reflux disease. *Surg Endosc* 24:2647-2669
21. Eren S, Gumus H, Okur A (2003) A rare cause of intestinal obstruction in the adult: Morgagni's hernia. *Hernia* 7:97-99
22. Mittal SK, Awad ZT, Tasset M, Filipi CJ, Dickason TJ, Shinno Y, Marsh RE, Tomonaga TJ, Lerner C (2000) The preoperative predictability of the short esophagus in patients with stricture or paraesophageal hernia. *Surg Endosc* 14:464-468
23. Morcos SK (2003) Review article: Effects of radiographic contrast media on the lung. *Br J Radiol* 76:290-295
24. Eren S, Ciris F (2005) Diaphragmatic hernia: diagnostic approaches with review of the literature. *Eur J Radiol* 54:448-459
25. Swanstrom LL, Jobe BA, Kinzie LR, Horvath KD (1999) Esophageal motility and outcomes following laparoscopic paraesophageal hernia repair and fundoplication. *Am J Surg* 177:359-363
26. Boushey RP, Moloo H, Burpee S, Schlachta CM, Poulin EC, Haggart F, Trottier DC, Mamazza J (2008) Laparoscopic repair of paraesophageal hernias: a Canadian experience. *Can J Surg* 51:355-360
27. Shih WJ, Milan PP (2005) Gastric-emptying scintigraphy of type III hiatal hernia: a case report. *J Nucl Med Technol* 33:83-85
28. Khouzam RN, Akhtar A, Minderman D, Kaiser J, D'Cruz IA (2007) Echocardiographic aspects of hiatal hernia: A review. *J Clin Ultrasound* 35:196-203



29. Fornari F, Gurski RR, Navarini D, Thiesen V, Mestriner LH, Madalosso CA (2010) Clinical utility of endoscopy and barium swallow X-ray in the diagnosis of sliding hiatal hernia in morbidly obese patients: a study before and after gastric bypass. *Obes Surg* 20:702-708
30. Gourgiotis S, Vougas V, Germanos S, Baratsis S (2006) Acute gastric volvulus: diagnosis and management over 10 years. *Dig Surg* 23:169-172
31. Shafii AE, Agle SC, Zervos EE (2009) Perforated gastric corpus in a strangulated paraesophageal hernia: a case report. *J Med Case Reports* 3:6507
32. Chang CC, Tseng CL, Chang YC (2009) A surgical emergency due to an incarcerated paraesophageal hernia. *Am J Emerg Med* 27:134 e131-133
33. Scheffer RC, Bredenoord AJ, Hebbard GS, Smout AJ, Samsom M (2010) Effect of proximal gastric volume on hiatal hernia. *Neurogastroenterol Motil* 22:552-556, e120
34. Fornari F, Madalosso CA, Farre R, Gurski RR, Thiesen V, Callegari-Jacques SM (2010) The role of gastro-oesophageal pressure gradient and sliding hiatal hernia on pathological gastro-oesophageal reflux in severely obese patients. *Eur J Gastroenterol Hepatol* 22:404-411
35. Gordon C, Kang JY, Neild PJ, Maxwell JD (2004) The role of the hiatus hernia in gastro-oesophageal reflux disease. *Aliment Pharmacol Ther* 20:719-732
36. Al-Tashi M, Rejchrt S, Kopacova M, Tycova V, Siroky M, Repak R, Tacheci I, Douda T, Cyrany J, Fejfar T, Hulek P, Bukac J, Bures J (2008) Hiatal hernia and Barrett's oesophagus impact on symptoms occurrence and complications. *Casopis lekaru ceskych* 147:564-568
37. Fujiwara Y, Nakao K, Inoue T, Koishi K, Nishio Y, Yagyu R, Nakagawa K, Yamamura T (2006) Clinical significance of hiatal hernia in the development of gastroesophageal reflux after distal gastrectomy for cancer of the stomach. *J Gastroenterol Hepatol* 21:1103-1107
38. Siu CW, Jim MH, Ho HH, Chu F, Chan HW, Lau CP, Tse HF (2005) Recurrent acute heart failure caused by sliding hiatus hernia. *Postgrad Med J* 81:268-269
39. Hashemi M, Sillin LF, Peters JH (1999) Current concepts in the management of paraesophageal hiatal hernia. *J Clin Gastroenterol* 29:8-13
40. Polomsky M, Siddall KA, Salvador R, Dubecz A, Donahue LA, Raymond D, Jones C, Watson TJ, Peters JH (2009) Association of kyphosis and spinal skeletal abnormalities with intrathoracic stomach: a link toward understanding its pathogenesis. *J Am Coll Surg* 208:562-569
41. Low DE, Simchuk EJ (2002) Effect of paraesophageal hernia repair on pulmonary function. *Ann Thorac Surg* 74:333-337; discussion 337
42. Ellis FH, Jr., Crozier RE, Shea JA (1986) Paraesophageal hiatus hernia. *Arch Surg*



121:416-420

43. Hunter JG, Smith CD, Branum GD, Waring JP, Trus TL, Cornwell M, Galloway K (1999) Laparoscopic fundoplication failures: patterns of failure and response to fundoplication revision. *Ann Surg* 230:595-604; discussion 604-596
44. Treacy PJ, Jamieson GG (1987) An approach to the management of para-oesophageal hiatus hernias. *Aust N Z J Surg* 57:813-817
45. Stylopoulos N, Gazelle GS, Rattner DW (2002) Paraesophageal hernias: operation or observation? *Ann Surg* 236:492-500; discussion 500-491
46. Hill LD (1973) Incarcerated paraesophageal hernia. A surgical emergency. *Am J Surg* 126:286-291
47. Skinner DB, Belsey RH (1967) Surgical management of esophageal reflux and hiatus hernia. Long-term results with 1,030 patients. *J Thorac Cardiovasc Surg* 53:33-54
48. Harriss DR, Graham TR, Galea M, Salama FD (1992) Paraoesophageal hiatal hernias: when to operate. *Journal of the Royal College of Surgeons of Edinburgh* 37:97-98
49. Louie BE, Blitz M, Farivar AS, Orlina J, Aye RW (2011) Repair of symptomatic giant paraesophageal hernias in elderly (>70 years) patients results in improved quality of life. *J Gastrointest Surg* 15:389-396
50. Sihvo EI, Salo JA, Rasanen JV, Rantanen TK (2009) Fatal complications of adult paraesophageal hernia: a population-based study. *J Thorac Cardiovasc Surg* 137:419-424
51. Polomsky M, Jones CE, Sepesi B, O'Connor M, Matousek A, Hu R, Raymond DP, Little VR, Watson TJ, Peters JH (2010) Should elective repair of intrathoracic stomach be encouraged? *J Gastrointest Surg* 14:203-210
52. Bawahab M, Mitchell P, Church N, Debru E (2009) Management of acute paraesophageal hernia. *Surg Endosc* 23:255-259
53. Allen MS, Trastek VF, Deschamps C, Pairolero PC (1993) Intrathoracic stomach. Presentation and results of operation. *J Thorac Cardiovasc Surg* 105:253-258; discussion 258-259
54. Hallissey MT, Ratliff DA, Temple JG (1992) Paraesophageal hiatus hernia: surgery for all ages. *Annals of the Royal College of Surgeons of England* 74:23-25
55. Pitcher DE, Curet MJ, Martin DT, Vogt DM, Mason J, Zucker KA (1995) Successful laparoscopic repair of paraesophageal hernia. *Arch Surg* 130:590-596
56. Gantert WA, Patti MG, Arcerito M, Feo C, Stewart L, DePinto M, Bhojru S, Rangel S,



Tyrrell D, Fujino Y, Mulvihill SJ, Way LW (1998) Laparoscopic repair of paraesophageal hiatal hernias. *J Am Coll Surg* 186:428-432; discussion 432-423

57. Carlson MA, Condon RE, Ludwig KA, Schulte WJ (1998) Management of intrathoracic stomach with polypropylene mesh prosthesis reinforced transabdominal hiatus hernia repair. *J Am Coll Surg* 187:227-230

58. Katkhouda N, Mavor E, Achanta K, Friedlander MH, Grant SW, Essani R, Mason RJ, Foster M, Mouiel J (2000) Laparoscopic repair of chronic intrathoracic gastric volvulus. *Surgery* 128:784-790

59. Koger KE, Stone JM (1993) Laparoscopic reduction of acute gastric volvulus. *Am Surg* 59:325-328

60. Anderson PG, Watson DI (1999) A new surgical technique for the silicone gastric band in the presence of a large hiatus hernia. *Obes Surg* 9:202-204; discussion 204-205

61. Dolan K, Finch R, Fielding G (2003) Laparoscopic gastric banding and crural repair in the obese patient with a hiatal hernia. *Obes Surg* 13:772-775

62. Landen S (2005) Simultaneous paraesophageal hernia repair and gastric banding. *Obes Surg* 15:435-438

63. Frezza EE, Barton A, Wachtel MS (2008) Crural repair permits morbidly obese patients with not large hiatal hernia to choose laparoscopic adjustable banding as a bariatric surgical treatment. *Obes Surg* 18:583-588

64. Angrisani L, Iovino P, Lorenzo M, Santoro T, Sabbatini F, Claar E, Nicodemi O, Persico G, Tesauro B (1999) Treatment of morbid obesity and gastroesophageal reflux with hiatal hernia by Lap-Band. *Obes Surg* 9:396-398

65. Dixon JB, O'Brien PE (1999) Gastroesophageal reflux in obesity: the effect of lap-band placement. *Obes Surg* 9:527-531

66. Gulkarov I, Wetterau M, Ren CJ, Fielding GA (2008) Hiatal hernia repair at the initial laparoscopic adjustable gastric band operation reduces the need for reoperation. *Surg Endosc* 22:1035-1041

67. Flanagan BA, Mitchell MT, Thistlethwaite WA, Alverdy JC (2010) Diagnosis and treatment of atypical presentations of hiatal hernia following bariatric surgery. *Obes Surg* 20:386-392

68. Salvador-Sanchis JL, Martinez-Ramos D, Herfarth A, Rivadulla-Serrano I, Ibanez-Belenguer M, Hoashi JS (2010) Treatment of morbid obesity and hiatal paraesophageal hernia by laparoscopic Roux-en-Y gastric bypass. *Obes Surg* 20:801-803

69. Mittal SK, Bikhchandani J, Gurney O, Yano F, Lee T (2010) Outcomes after repair of the



intrathoracic stomach: objective follow-up of up to 5 years. *Surg Endosc*

70. Korwar V, Peters M, Adjepong S, Sigurdsson A (2009) Laparoscopic hiatus hernia repair and simultaneous sleeve gastrectomy: a novel approach in the treatment of gastroesophageal reflux disease associated with morbid obesity. *J Laparoendosc Adv Surg Tech A* 19:761-763

71. Merchant AM, Cook MW, Srinivasan J, Davis SS, Sweeney JF, Lin E (2009) Comparison between laparoscopic paraesophageal hernia repair with sleeve gastrectomy and paraesophageal hernia repair alone in morbidly obese patients. *Am Surg* 75:620-625

72. Varela JE (2009) Laparoscopic biomesh hiatoplasty and sleeve gastrectomy in a morbidly obese patient with hiatal hernia. *Surg Obes Relat Dis* 5:707-709

73. Iqbal A, Kakarlapudi GV, Awad ZT, Haynatzki G, Turaga KK, Karu A, Fritz K, Haider M, Mittal SK, Filipi CJ (2006) Assessment of diaphragmatic stressors as risk factors for symptomatic failure of laparoscopic nissen fundoplication. *J Gastrointest Surg* 10:12-21

74. Poulouse BK, Gosen C, Marks JM, Khaitan L, Rosen MJ, Onders RP, Trunzo JA, Ponsky JL (2008) Inpatient mortality analysis of paraesophageal hernia repair in octogenarians. *J Gastrointest Surg* 12:1888-1892

75. Gupta A, Chang D, Steele KE, Schweitzer MA, Lyn-Sue J, Lidor AO (2008) Looking beyond age and co-morbidities as predictors of outcomes in paraesophageal hernia repair. *J Gastrointest Surg* 12:2119-2124

76. Wilson LJ, Ma W, Hirschowitz BI (1999) Association of obesity with hiatal hernia and esophagitis. *Am J Gastroenterol* 94:2840-2844

77. Perez AR, Moncure AC, Rattner DW (2001) Obesity adversely affects the outcome of antireflux operations. *Surg Endosc* 15:986-989

78. Aly A, Munt J, Jamieson GG, Ludemann R, Devitt PG, Watson DI (2005) Laparoscopic repair of large hiatal hernias. *Br J Surg* 92:648-653

79. Koch OO, Asche KU, Berger J, Weber E, Granderath FA, Pointner R (2011) Influence of the size of the hiatus on the rate of reherniation after laparoscopic fundoplication and refundoplication with mesh hiatoplasty. *Surg Endosc* 25:1024-1030

80. Shamiyeh A, Szabo K, Granderath FA, Syre G, Wayand W, Zehetner J (2010) The esophageal hiatus: what is the normal size? *Surg Endosc* 24:988-991

81. Braghetto I, Korn O, Csendes A, Burdiles P, Valladares H, Brunet L (2010) Postoperative results after laparoscopic approach for treatment of large hiatal hernias: is mesh always needed? Is the addition of an antireflux procedure necessary? *International surgery* 95:80-87

82. Pearson JB, Gray JG (1967) Oesophageal hiatus hernia: long-term results of the



conventional thoracic operation. *Br J Surg* 54:530-533

83. Yano F, Stadlhuber RJ, Tsuboi K, Gerhardt J, Filipi CJ, Mittal SK (2009) Outcomes of surgical treatment of intrathoracic stomach. *Dis Esophagus* 22:284-288

84. Velanovich V, Karmy-Jones R (2001) Surgical management of paraesophageal hernias: outcome and quality of life analysis. *Dig Surg* 18:432-437; discussion 437-438

85. DeMeester SR, Sillin LF, Lin HW, Gurski RR (2003) Increasing esophageal length: a comparison of laparoscopic versus transthoracic esophageal mobilization with and without vagal trunk division in pigs. *J Am Coll Surg* 197:558-564

86. Maziak DE, Todd TR, Pearson FG (1998) Massive hiatus hernia: evaluation and surgical management. *J Thorac Cardiovasc Surg* 115:53-60; discussion 61-52

87. Luketich JD, Raja S, Fernando HC, Campbell W, Christie NA, Buenaventura PO, Weigel TL, Keenan RJ, Schauer PR (2000) Laparoscopic repair of giant paraesophageal hernia: 100 consecutive cases. *Ann Surg* 232:608-618

88. Geha AS, Massad MG, Snow NJ, Baue AE (2000) A 32-year experience in 100 patients with giant paraesophageal hernia: the case for abdominal approach and selective antireflux repair. *Surgery* 128:623-630

89. Haider M, Iqbal A, Salinas V, Karu A, Mittal SK, Filipi CJ (2006) Surgical repair of recurrent hiatal hernia. *Hernia* 10:13-19

90. Chrysos E, Tsiaoussis J, Athanasakis E, Zoras O, Vassilakis JS, Xynos E (2002) Laparoscopic vs open approach for Nissen fundoplication. A comparative study. *Surg Endosc* 16:1679-1684

91. Cuschieri A, Shimi S, Nathanson LK (1992) Laparoscopic reduction, crural repair, and fundoplication of large hiatal hernia. *Am J Surg* 163:425-430

92. Congreve DP (1992) Laparoscopic paraesophageal hernia repair. *J Laparoendosc Surg* 2:45-48

93. Behrns KE, Schlinkert RT (1996) Laparoscopic management of paraesophageal hernia: early results. *J Laparoendosc Surg* 6:311-317

94. Perdakis G, Hinder RA, Filipi CJ, Walenz T, McBride PJ, Smith SL, Katada N, Klingler PJ (1997) Laparoscopic paraesophageal hernia repair. *Arch Surg* 132:586-589; discussion 590-581

95. Edye MB, Canin-Endres J, Gattorno F, Salky BA (1998) Durability of laparoscopic repair of paraesophageal hernia. *Ann Surg* 228:528-535



96. Schauer PR, Ikramuddin S, McLaughlin RH, Graham TO, Slivka A, Lee KK, Schraut WH, Luketich JD (1998) Comparison of laparoscopic versus open repair of paraesophageal hernia. *Am J Surg* 176:659-665
97. Oelschlager BK, Pellegrini CA (2001) Paraesophageal hernias: open, laparoscopic, or thoracic repair? *Chest Surg Clin N Am* 11:589-603
98. Rosen M, Ponsky J (2003) Laparoscopic repair of giant paraesophageal hernias: an update for internists. *Cleve Clin J Med* 70:511-514
99. Low DE, Unger T (2005) Open repair of paraesophageal hernia: reassessment of subjective and objective outcomes. *Ann Thorac Surg* 80:287-294
100. Diez Tabernilla M, Ruiz-Tovar J, Grajal Marino R, Calero Garcia P, Pina Hernandez JD, Chames Vaisman A, Morales Castineiras V, Sanjuanbenito Dehesa A, Martinez Molina E, Fresneda Moreno V (2009) Paraesophageal hiatal hernia. Open vs. laparoscopic surgery. *Rev Esp Enferm Dig* 101:706-711
101. Zehetner J, Demeester SR, Ayazi S, Kilday P, Augustin F, Hagen JA, Lipham JC, Sohn HJ, Demeester TR (2011) Laparoscopic versus open repair of paraesophageal hernia: the second decade. *J Am Coll Surg* 212:813-820
102. Watson DI, Davies N, Devitt PG, Jamieson GG (1999) Importance of dissection of the hernial sac in laparoscopic surgery for large hiatal hernias. *Arch Surg* 134:1069-1073
103. Poncet G, Robert M, Roman S, Boulez JC (2010) Laparoscopic Repair of Large Hiatal Hernia Without Prosthetic Reinforcement: Late Results and Relevance of Anterior Gastropexy. *J Gastrointest Surg*
104. Zehetner J, Lipham JC, Ayazi S, Oezcelik A, Abate E, Chen W, Demeester SR, Sohn HJ, Banki F, Hagen JA, Dickey M, Demeester TR (2010) A simplified technique for intrathoracic stomach repair: laparoscopic fundoplication with Vicryl mesh and BioGlue crural reinforcement. *Surg Endosc* 24:675-679
105. Edye M, Salky B, Posner A, Fierer A (1998) Sac excision is essential to adequate laparoscopic repair of paraesophageal hernia. *Surg Endosc* 12:1259-1263
106. Trus TL, Bax T, Richardson WS, Branum GD, Mauren SJ, Swanstrom LL, Hunter JG (1997) Complications of laparoscopic paraesophageal hernia repair. *J Gastrointest Surg* 1:221-227; discussion 228
107. Leeder PC, Smith G, Dehn TC (2003) Laparoscopic management of large paraesophageal hiatal hernia. *Surg Endosc* 17:1372-1375
108. Hashemi M, Peters JH, DeMeester TR, Huprich JE, Quek M, Hagen JA, Crookes PF, Theisen J, DeMeester SR, Sillin LF, Bremner CG (2000) Laparoscopic repair of large type III



hiatal hernia: objective followup reveals high recurrence rate. *J Am Coll Surg* 190:553-560; discussion 560-551

109. Wiechmann RJ, Ferguson MK, Naunheim KS, McKesey P, Hazelrigg SJ, Santucci TS, Macherey RS, Landreneau RJ (2001) Laparoscopic management of giant paraesophageal herniation. *Ann Thorac Surg* 71:1080-1086; discussion 1086-1087

110. Varga G, Cseke L, Kalmar K, Horvath OP (2008) Laparoscopic repair of large hiatal hernia with teres ligament: midterm follow-up: a new surgical procedure. *Surg Endosc* 22:881-884

111. Quilici PJ, McVay C, Tovar A (2009) Laparoscopic antireflux procedures with hepatic shoulder technique for the surgical management of large paraesophageal hernias and gastroesophageal reflux disease. *Surg Endosc* 23:2620-2623

112. Ochsner JL, Hughes JP, Mills NL (1975) Repair of hiatal hernia: description and long-term results of a technique. *Am Surg* 41:626-631

113. El Sherif A, Yano F, Mittal S, Filipi CJ (2006) Collagen metabolism and recurrent hiatal hernia: cause and effect? *Hernia* 10:511-520

114. Edelman DS (1995) Laparoscopic paraesophageal hernia repair with mesh. *Surgical laparoscopy & endoscopy* 5:32-37

115. Kuster GG, Gilroy S (1993) Laparoscopic technique for repair of paraesophageal hiatal hernias. *J Laparoendosc Surg* 3:331-338

116. Basso N, Rosato P, De Leo A, Genco A, Rea S, Neri T (1999) "Tension-free" hiatoplasty, gastrophrenic anchorage, and 360 degrees fundoplication in the laparoscopic treatment of paraesophageal hernia. *Surg Laparosc Endosc Percutan Tech* 9:257-262

117. Casaccia M, Torelli P, Panaro F, Cavaliere D, Ventura A, Valente U (2002) Laparoscopic physiological hiatoplasty for hiatal hernia: new composite "A"-shaped mesh. Physical and geometrical analysis and preliminary clinical results. *Surg Endosc* 16:1441-1445

118. Frantzides CT, Madan AK, Carlson MA, Stavropoulos GP (2002) A prospective, randomized trial of laparoscopic polytetrafluoroethylene (PTFE) patch repair vs simple cruroplasty for large hiatal hernia. *Arch Surg* 137:649-652

119. Granderath FA, Schweiger UM, Kamolz T, Asche KU, Pointner R (2005) Laparoscopic Nissen fundoplication with prosthetic hiatal closure reduces postoperative intrathoracic wrap herniation: preliminary results of a prospective randomized functional and clinical study. *Arch Surg* 140:40-48

120. Rice TW, Blackstone EH (2007) Does a biologic prosthesis really reduce recurrence after laparoscopic paraesophageal hernia repair? *Ann Surg* 246:1116-1117; author reply 1117-1118



121. Oelschlager BK, Pellegrini CA, Hunter JG, Brunt ML, Soper NJ, Sheppard BC, Polissar NL, Neradilek MB, Mitsumori LM, Rohrmann CA, Swanstrom LL (2011) Biologic Prosthesis to Prevent Recurrence after Laparoscopic Paraesophageal Hernia Repair: Long-term Follow-up from a Multicenter, Prospective, Randomized Trial. *J Am Coll Surg* 213:461-468
122. Turkcapar A, Kepenekci I, Mahmoud H, Tuzuner A (2007) Laparoscopic fundoplication with prosthetic hiatal closure. *World J Surg* 31:2169-2176
123. Johnson JM, Carbonell AM, Carmody BJ, Jamal MK, Maher JW, Kellum JM, DeMaria EJ (2006) Laparoscopic mesh hiatoplasty for paraesophageal hernias and funduplications: a critical analysis of the available literature. *Surg Endosc* 20:362-366
124. Muller-Stich BP, Linke GR, Borovicka J, Marra F, Warschkow R, Lange J, Mehrabi A, Koninger J, Gutt CN, Zerz A (2008) Laparoscopic mesh-augmented hiatoplasty as a treatment of gastroesophageal reflux disease and hiatal hernias-preliminary clinical and functional results of a prospective case series. *Am J Surg* 195:749-756
125. Granderath FA, Carlson MA, Champion JK, Szold A, Basso N, Pointner R, Frantzides CT (2006) Prosthetic closure of the esophageal hiatus in large hiatal hernia repair and laparoscopic antireflux surgery. *Surg Endosc* 20:367-379
126. Casaccia M, Torelli P, Panaro F, Cavaliere D, Saltalamacchia L, Troilo BM, Savelli A, Valente U (2005) Laparoscopic tension-free repair of large paraesophageal hiatal hernias with a composite A-shaped mesh: two-year follow-up. *J Laparoendosc Adv Surg Tech A* 15:279-284
127. Targarona EM, Bendahan G, Balague C, Garriga J, Trias M (2004) Mesh in the hiatus: a controversial issue. *Arch Surg* 139:1286-1296; discussion 1296
128. Ringley CD, Bochkarev V, Ahmed SI, Vitamvas ML, Oleynikov D (2006) Laparoscopic hiatal hernia repair with human acellular dermal matrix patch: our initial experience. *Am J Surg* 192:767-772
129. Lee E, Frisella MM, Matthews BD, Brunt LM (2007) Evaluation of acellular human dermis reinforcement of the crural closure in patients with difficult hiatal hernias. *Surg Endosc* 21:641-645
130. Shenfine J, Barbour A, Martin I, Smithers BM, Gotley DC (2008) Consideration of mesh-related complications. *Annals of the Royal College of Surgeons of England* 90:175-176; author reply 176
131. Griffith PS, Valenti V, Qurashi K, Martinez-Isla A (2008) Rejection of goretex mesh used in prosthetic cruroplasty: a case series. *Int J Surg* 6:106-109
132. Stadlhuber RJ, Sherif AE, Mittal SK, Fitzgibbons RJ, Jr., Michael Brunt L, Hunter JG, Demeester TR, Swanstrom LL, Daniel Smith C, Filipi CJ (2009) Mesh complications after prosthetic reinforcement of hiatal closure: a 28-case series. *Surg Endosc* 23:1219-1226



133. Blatnik J, Jin J, Rosen M (2008) Abdominal hernia repair with bridging acellular dermal matrix--an expensive hernia sac. *Am J Surg* 196:47-50
134. Angelchik JP, Cohen R (1979) A new surgical procedure for the treatment of gastroesophageal reflux and hiatal hernia. *Surgery, gynecology & obstetrics* 148:246-248
135. Rumstadt B, Kahler G, Mickisch O, Schilling D (2008) Gastric mesh erosion after hiatoplasty for recurrent paraesophageal hernia. *Endoscopy* 40 Suppl 2:E70
136. Diwan TS, Ujiki MB, Dunst CM, Swanstrom LL (2008) Biomes mesh placement in laparoscopic repair of paraesophageal hernias. *Surgical innovation* 15:184-187
137. Jansen M, Otto J, Jansen PL, Anurov M, Titkova S, Willis S, Rosch R, Ottinger A, Schumpelick V (2007) Mesh migration into the esophageal wall after mesh hiatoplasty: comparison of two alloplastic materials. *Surg Endosc* 21:2298-2303
138. Kempainen E, Kiviluoto T (2000) Fatal cardiac tamponade after emergency tension-free repair of a large paraesophageal hernia. *Surg Endosc* 14:593
139. Fortelny RH, Petter-Puchner AH, Glaser KS (2009) Fibrin sealant (Tissucol) for the fixation of hiatal mesh in the repair of giant paraesophageal hernia: a case report. *Surg Laparosc Endosc Percutan Tech* 19:e91-94
140. Wu JS, Dunnegan DL, Soper NJ (1999) Clinical and radiologic assessment of laparoscopic paraesophageal hernia repair. *Surg Endosc* 13:497-502
141. Walther B, DeMeester TR, Lafontaine E, Courtney JV, Little AG, Skinner DB (1984) Effect of paraesophageal hernia on sphincter function and its implication on surgical therapy. *Am J Surg* 147:111-116
142. Fuller CB, Hagen JA, DeMeester TR, Peters JH, Ritter M, Bremner CG (1996) The role of fundoplication in the treatment of type II paraesophageal hernia. *J Thorac Cardiovasc Surg* 111:655-661
143. Morris-Stiff G, Hassn A (2008) Laparoscopic paraoesophageal hernia repair: fundoplication is not usually indicated. *Hernia* 12:299-302
144. Mark LA, Okrainec A, Ferri LE, Feldman LS, Mayrand S, Fried GM (2008) Comparison of patient-centered outcomes after laparoscopic Nissen fundoplication for gastroesophageal reflux disease or paraesophageal hernia. *Surg Endosc* 22:343-347
145. Awad ZT, Filipi CJ, Mittal SK, Roth TA, Marsh RE, Shiino Y, Tomonaga T (2000) Left side thoracoscopically assisted gastroplasty: a new technique for managing the shortened esophagus. *Surg Endosc* 14:508-512
146. Furnee EJ, Draaisma WA, Simmermacher RK, Stapper G, Broeders IA (2010) Long-term



symptomatic outcome and radiologic assessment of laparoscopic hiatal hernia repair. *Am J Surg* 199:695-701

147. O'Rourke RW, Khajanchee YS, Urbach DR, Lee NN, Lockhart B, Hansen PD, Swanstrom LL (2003) Extended transmediastinal dissection: an alternative to gastroplasty for short esophagus. *Arch Surg* 138:735-740

148. Rathore MA, Andrabi SI, Bhatti MI, Najfi SM, McMurray A (2007) Metaanalysis of recurrence after laparoscopic repair of paraesophageal hernia. *JSL* 11:456-460

149. Luketich JD, Nason KS, Christie NA, Pennathur A, Jobe BA, Landreneau RJ, Schuchert MJ (2010) Outcomes after a decade of laparoscopic giant paraesophageal hernia repair. *J Thorac Cardiovasc Surg* 139:395-404, 404 e391

150. Legner A, Tsuboi K, Bathla L, Lee T, Morrow LE, Mittal SK (2010) Reoperative antireflux surgery for dysphagia. *Surg Endosc*

151. Rothenberg SS, Chin A (2010) Laparoscopic Collis-Nissen for Recurrent Severe Reflux in Pediatric Patients with Esophageal Atresia and Recurrent Hiatal Hernia. *J Laparoendosc Adv Surg Tech A*

152. Oelschlager BK, Yamamoto K, Woltman T, Pellegrini C (2008) Vagotomy during hiatal hernia repair: a benign esophageal lengthening procedure. *J Gastrointest Surg* 12:1155-1162

153. Johnson AB, Oddsdottir M, Hunter JG (1998) Laparoscopic Collis gastroplasty and Nissen fundoplication. A new technique for the management of esophageal foreshortening. *Surg Endosc* 12:1055-1060

154. Gastal OL, Hagen JA, Peters JH, Campos GM, Hashemi M, Theisen J, Bremner CG, DeMeester TR (1999) Short esophagus: analysis of predictors and clinical implications. *Arch Surg* 134:633-636; discussion 637-638

155. Garg N, Yano F, Filipi CJ, Mittal SK (2009) Long-term symptomatic outcomes after Collis gastroplasty with fundoplication. *Dis Esophagus* 22:532-538

156. Ponsky J, Rosen M, Fanning A, Malm J (2003) Anterior gastropexy may reduce the recurrence rate after laparoscopic paraesophageal hernia repair. *Surg Endosc* 17:1036-1041

157. Diaz S, Brunt LM, Klingensmith ME, Frisella PM, Soper NJ (2003) Laparoscopic paraesophageal hernia repair, a challenging operation: medium-term outcome of 116 patients. *J Gastrointest Surg* 7:59-66; discussion 66-57

158. Rosenberg J, Jacobsen B, Fischer A (2006) Fast-track giant paraoesophageal hernia repair using a simplified laparoscopic technique. *Langenbecks Arch Surg* 391:38-42

159. Agwunobi AO, Bancewicz J, Attwood SE (1998) Simple laparoscopic gastropexy as the



initial treatment of paraoesophageal hiatal hernia. *Br J Surg* 85:604-606

160. Debray C, Poinard G, Deporte A (1965) ["Gastric distension-tachycardia" syndrome, an occasionally severe complication of operated hiatal hernia]. *Actual Hepatogastroenterol (Paris)* 1:304-312
161. Jobe BA, Aye RW, Deveney CW, Domreis JS, Hill LD (2002) Laparoscopic management of giant type III hiatal hernia and short esophagus. Objective follow-up at three years. *J Gastrointest Surg* 6:181-188; discussion 188
162. Frantzides CT, Madan AK, Carlson MA, Zeni TM, Zografakis JG, Moore RM, Meiselman M, Luu M, Ayiomamitis GD (2009) Laparoscopic revision of failed fundoplication and hiatal herniorrhaphy. *J Laparoendosc Adv Surg Tech A* 19:135-139
163. Granderath FA, Granderath UM, Pointner R (2008) Laparoscopic revisional fundoplication with circular hiatal mesh prosthesis: the long-term results. *World J Surg* 32:999-1007
164. Chana J, Crabbe DC, Spitz L (1996) Familial hiatus hernia and gastro-oesophageal reflux. *Eur J Pediatr Surg* 6:175-176
165. Hsu JY, Chen SJ, Wang JK, Ni YH, Chang MH, Wu MH (2005) Clinical implication of hiatal hernia in patients with right isomerism. *Acta Paediatr* 94:1248-1252
166. Jetley NK, Al-Assiri AH, Al Awadi D (2009) Congenital para esophageal hernia: a 10 year experience from Saudi Arabia. *Indian J Pediatr* 76:489-493
167. Asling B, Jirholt J, Hammond P, Knutsson M, Walentinsson A, Davidson G, Agreus L, Lehmann A, Lagerstrom-Fermer M (2009) Collagen type III alpha I is a gastro-oesophageal reflux disease susceptibility gene and a male risk factor for hiatus hernia. *Gut* 58:1063-1069
168. Gorenstein A, Cohen AJ, Cordova Z, Witzling M, Krutman B, Serour F (2001) Hiatal hernia in pediatric gastroesophageal reflux. *J Pediatr Gastroenterol Nutr* 33:554-557
169. Al-Salem AH (2000) Congenital paraesophageal hernia in infancy and childhood. *Saudi Med J* 21:164-167
170. Karpelowsky JS, Wieselthaler N, Rode H (2006) Primary paraesophageal hernia in children. *J Pediatr Surg* 41:1588-1593
171. Yazici M, Karaca I, Etensel B, Temir G, Gunsar C, Guclu C, Mutaf O (2003) Paraesophageal hiatal hernias in children. *Dis Esophagus* 16:210-213
172. Johnston BT, Carre IJ, Thomas PS, Collins BJ (1995) Twenty to 40 year follow up of infantile hiatal hernia. *Gut* 36:809-812
173. Bettolli M, Rubin SZ, Gutauskas A (2008) Large paraesophageal hernias in children. *Early*



experience with laparoscopic repair. *Eur J Pediatr Surg* 18:72-74

174. van der Zee DC, Bax NM, Kramer WL, Mokhaberi B, Ure BM (2001) Laparoscopic management of a paraesophageal hernia with intrathoracic stomach in infants. *Eur J Pediatr Surg* 11:52-54

175. Avansino JR, Lorenz ML, Hendrickson M, Jolley SG (1999) Characterization and management of paraesophageal hernias in children after antireflux operation. *J Pediatr Surg* 34:1610-1614

176. St Peter SD, Barnhart DC, Ostlie DJ, Tsao K, Leys CM, Sharp SW, Bartle D, Morgan T, Harmon CM, Georgeson KE, Holcomb GW, 3rd (2011) Minimal vs extensive esophageal mobilization during laparoscopic fundoplication: a prospective randomized trial. *J Pediatr Surg* 46:163-168